

Clinical signs, pathology and dose-dependent survival of adult wood frogs, *Rana sylvatica*, inoculated orally with frog virus 3 (*Ranavirus* sp., *Iridoviridae*)

María J. Forzán,^{1,2} Kathleen M. Jones,² Raphaël V. Vanderstichel,³ John Wood,⁴ Frederick S. B. Kibenge,² Thijs Kuiken,⁵ Wytamma Wirth,⁶ Ellen Ariel⁶ and Pierre-Yves Daoust^{1,2}

Correspondence

María J. Forzán
mforzan@upe.ca

¹Canadian Wildlife Health Cooperative

²Department of Pathology and Microbiology, Atlantic Veterinary College, University of Prince Edward Island, Canada

³Department of Health Management, Atlantic Veterinary College, University of Prince Edward Island, Canada

⁴Pisces Molecular LLC, Boulder, Colorado, USA

⁵Department of Viroscience, Erasmus University Medical Centre, Rotterdam, The Netherlands

⁶School of Veterinary and Biomedical Sciences, James Cook University, Townsville, Australia

Amphibian populations suffer massive mortalities from infection with frog virus 3 (FV3, genus *Ranavirus*, family *Iridoviridae*), a pathogen also involved in mortalities of fish and reptiles. Experimental oral infection with FV3 in captive-raised adult wood frogs, *Rana sylvatica* (*Lithobates sylvaticus*), was performed as the first step in establishing a native North American animal model of ranaviral disease to study pathogenesis and host response. Oral dosing was successful; LD₅₀ was 10^{2.93} (2.42–3.44) p.f.u. for frogs averaging 35 mm in length. Onset of clinical signs occurred 6–14 days post-infection (p.i.) (median 11 days p.i.) and time to death was 10–14 days p.i. (median 12 days p.i.). Each tenfold increase in virus dose increased the odds of dying by 23-fold and accelerated onset of clinical signs and death by approximately 15%. Ranavirus DNA was demonstrated in skin and liver of all frogs that died or were euthanized because of severe clinical signs. Shedding of virus occurred in faeces (7–10 days p.i.; 3–4.5 days before death) and skin sheds (10 days p.i.; 0–1.5 days before death) of some frogs dead from infection. Most common lesions were dermal erosion and haemorrhages; haematopoietic necrosis in bone marrow, kidney, spleen and liver; and necrosis in renal glomeruli, tongue, gastrointestinal tract and urinary bladder mucosa. Presence of ranavirus in lesions was confirmed by immunohistochemistry. Intracytoplasmic inclusion bodies (probably viral) were present in the bone marrow and the epithelia of the oral cavity, gastrointestinal tract, renal tubules and urinary bladder. Our work describes a ranavirus–wood frog model and provides estimates that can be incorporated into ranavirus disease ecology models.

Received 7 October 2014

Accepted 8 January 2015

INTRODUCTION

Frog virus 3 (FV3), the type species of the genus *Ranavirus* (family *Iridoviridae*), was isolated more than 50 years ago (Granoff *et al.*, 1966) but not until the beginning of the 1990s was it recognized as the pathogen responsible for high mortality epizootics in fish, amphibians and reptiles (Chinchar *et al.*, 2009; Lesbarrères *et al.*, 2012). In 2008,

infection with *Ranavirus* sp. became one of only two notifiable diseases of amphibians listed by the World Organization for Animal Health (2013). Ranaviruses have been responsible for mass mortalities in wild and captive frogs and salamanders in north America, Asia, Australia and Europe (Gray *et al.*, 2009), and are currently the focus of intense research (Chinchar *et al.*, 2009). Experimental infections with various species and isolates of ranaviruses have been achieved through intraperitoneal injection (Tweedell & Granoff, 1968; Wolf *et al.*, 1968), immersion in viral suspension via water bath (Brunner *et al.*, 2005;

Three supplementary figures, one supplementary table and supplementary methods are available with the online Supplementary Material.

Harp & Petranksa, 2006; Cullen & Owens, 2002), exposure of cutaneous wounds to virus (Cunningham *et al.*, 2007) and oral administration (Wolf *et al.*, 1968; Hoverman *et al.*, 2010). Although the work of dozens of researchers, past and present, frequently focuses on experimental challenges with the original FV3 isolated in the 1960s (Granoff *et al.*, 1966), reported dosages vary, as do the species and developmental stage of the infected host. Research on FV3 is particularly relevant since many mortality events throughout the world are due to FV3 or FV3-like viruses (Chinchar, 2002). Similarly to other viruses, the dose and route of infection are important determinants of FV3 pathogenicity (virulence, type and severity of lesions) (Brunner *et al.*, 2005; Cullen & Owens, 2002; Cunningham *et al.*, 2007). Thus, the variability in experimental designs provides an abundance of valuable information but complicates comparisons and extrapolations. Amongst the multiple host species used in research, it is arguably in the African clawed frog, *Xenopus laevis*, that the host response of adult frogs to, and pathogenesis of, FV3 infection have been most extensively studied (Gantress *et al.*, 2003; Robert *et al.*, 2007, 2011). Adult *X. laevis* inoculated intraperitoneally with $10^{7.7}$ p.f.u. of FV3 show only transitory signs of disease that are correlated with the presence of viral DNA in the kidney; signs disappear 2 weeks post-infection (p.i.) while virus becomes undetectable in most tissues 1 month p.i. when specific anti-FV3 IgY antibody production peaks (Gantress *et al.*, 2003) although it may remain present in the kidney for several months (Robert *et al.*, 2007) and possibly result in excretion via urine-rich faeces (Gantress *et al.*, 2003). Unfortunately, *X. laevis* is a member of a family of frogs (Pipidae) not naturally present in North America or the rest of the northern hemisphere, which limits its regional relevance to the study of disease ecology in native amphibians. The anatomy and natural history of pipid frogs, which are restricted to tropical South America east of the Andes and to sub-Saharan Africa, differ significantly from those of frogs of the northern hemisphere: pipids are strictly aquatic and thus morphologically adapted to this environment with fully webbed feet, lateral-line organs, poorly developed to absent eyelids, no tongue and a diet composed mostly of zooplankton (Duellman & Trueb, 1994). The validity of extrapolating findings on pipids to native North American frogs, particularly regarding mode of transmission, carrier states and pathophysiology, should be questioned since phylogeny, life history and type of habitat have been suggested to influence host susceptibility and response to ranavirus infection (Hoverman *et al.*, 2011). A better representative of the life history of the majority of frogs in the northern hemisphere and of those North American species in which the majority of mortalities have been reported since 1997 (Hoverman *et al.*, 2011) is the family Ranidae, or true frogs. Ranid frogs are present across the entire northern hemisphere and extend the farthest north of any other amphibian species. The ranid anatomy, life history and reproductive strategy are those of the archetypical frog: mostly terrestrial (riparian, fossorial or occasionally arboreal), with a carnivorous/insectivorous diet, external

fertilization, and egg laying and larval development in water (Duellman & Trueb, 1994). Of the 29 North American species of ranids, at least 14 of which are known to be susceptible to ranavirus infection and disease (Miller *et al.*, 2011), the wood frog, *Rana sylvatica* (*Lithobates sylvaticus*), was proposed as a focus for research by participants at the First International Symposium on Ranaviruses (Lesbarrères *et al.*, 2012). Researchers at the Symposium emphasized the need for an amphibian model for viral challenge experiments that allows for comparisons amongst studies and provides data to incorporate into ecological disease models, and thus selected the wood frog given its life history, high susceptibility to disease caused by FV3 and widespread distribution in North America which makes it sympatric with many other native species (Lesbarrères *et al.*, 2012). Experimental infections in wood frog tadpoles suggest that the susceptibility of the species to infection and mortality due to FV3 and FV3-like viruses is similar to, or slightly higher than, that of other sympatric North American species (Hoverman *et al.*, 2011). To our knowledge, no reports exist of experimental infection of adult wood frogs. Establishing a useful model of FV3 infection in wood frogs will allow for comparisons with what is known to occur in *X. laevis* and, more importantly, provide information on the pathogenesis of the infection in a species designated a representative of frogs commonly affected by the disease.

One of the first steps in establishing a native North American animal model to study ranavirus pathogenesis and host response to infection is the determination of the dose of virus necessary to cause mortality in 50 % of individuals: LD₅₀. A known LD₅₀ allows for the design of virus challenge experiments with specific aims and for a meaningful comparison of results amongst studies. Along with a predetermined dose, it is necessary to find a route of administration that can mimic transmission in the wild, is easily employed and allows for the administration of precise dosages. As consumption of infected material (scavenging on infected carcasses) is a known route of ranavirus infection in wood frog tadpoles (Harp & Petranksa, 2006) and since oral dosing allows for the administration of predetermined viral concentrations, the oral route is likely to fulfil those requirements.

Our overall aim was to propose parameters that can become the standard for future ranavirus North American frog models. Our specific objectives were to establish the LD₅₀ of FV3 virus in 1-year-old captive-raised wood frogs when administered orally, determine parameters potentially useful in disease modelling such as length of incubation period, median survival time (ST₅₀) and odds of death at a certain viral dose, establish whether shedding occurs in faeces and skin sheds and describe the clinico-pathological changes resulting from infection.

RESULTS

The TCID₅₀ and p.f.u. of the FV3 stock were $10^{6.33}$ ml⁻¹ and $10^{7.73}$ p.f.u. ml⁻¹, respectively. The LD₅₀ was calculated as

$10^{2.93}$ p.f.u. per frog (95 % confidence interval (CI): $10^{2.42}$ – $10^{3.44}$ p.f.u. per frog) (Fig. S2, available in the online Supplementary Material).

Fifteen frogs in the groups inoculated with FV3, henceforth referred to as ‘fatally infected’, were euthanized because of severe clinical signs ($n=6$) or died ($n=9$) from the FV3 infection (Fig. 2). The remaining 19 frogs (including the four control frogs) exhibited no clinical signs, except for minimal petechiation of the hind feet (less than 10 petechiae in total, one frog in the $10^{3.43}$ p.f.u. group), and mild depression but without loss of posture or reflexes (one frog in the $10^{2.43}$ p.f.u. group), both on 14 days p.i. only. Clinical signs included regurgitation of food items, dazed stare or mild depression, severe depression with loss of withdrawal and/or righting reflex and widespread petechiation on the ventral surface of the skin (Table 1). An additional observation included as a clinical sign was the presence of a small (less than 0.5 cm in greatest diameter) ovoid pearly white bead found in the water dish of four of the fatally infected frogs but never produced by any of the survivors. It consisted of proteinaceous material (mucus) admixed with myriads of Gram-negative bacterial rods and a few rafts of cells (Fig. 1d–f). Although the origin of this bead could not be unequivocally determined as its production was never observed, it was assumed to have formed in the colon of terminally diseased frogs based on its faeces-like shape and its histological similarity to material present in the lumen of necrotic segments of the distal digestive tract.

Clinical signs in fatally infected frogs began between 6 and 14 days p.i. (median 11 days p.i.). Mortalities began at 10 days p.i. and ended on 14 days p.i. (median time to death, ST_{50} , 12 days p.i.). The interval between the onset of clinical

signs and death varied from 0 (<12 h based on time of the previous check) to 4.5 days (median 1 day) (Table 1). The onset of clinical signs was accelerated by 15 % (95 % CI 5–24 %, P value=0.001) and the ST_{50} was decreased by 16 % (95 % CI 6–25 %, P value=0.001) with every tenfold increase in dose, when dose was $\geq 10^{2.43}$ p.f.u.

The whole group of frogs involved in the experimental infection, including controls, measured an average (mean) of 35.0 mm in snout–vent (SV) length, with a median of 35.2 mm (range 29–42, mean 95 % CI 33.8–36.2) (Fig. 2). The fatally infected frogs averaged 32.9 mm with a median of 33.2 mm (range 29–37, mean 95 % CI 31.5–34.2). Although the frogs were not measured before the experiment, negligible growth would be expected to occur in 1-year-old animals over the short period of time the trial lasted (10–22 days), and thus measurements are assumed to reflect pre-infection lengths. Even accounting for the difference in size between groups as a potential confounding variable, the size of the frog (SV length) at time of death had a significant effect on the onset of clinical signs and ST_{50} (P values <0.001 and 0.001, respectively): every millimetre increase in length resulted in a 6 % (95 % CI 3–9 %) delay in onset of signs and a 5 % delay in death (95 % CI 2–8 %) when dose was $\geq 10^{2.43}$ p.f.u. The odds of dying increased 23-fold (P value=0.017) for every tenfold increase in dose. The effect of size on the probability of death, if any, could not be statically assessed (the model would not converge), possibly due to the small sample size.

PCR for ranavirus DNA was positive in the skin and liver of all fatally infected frogs (15/15); in frogs that survived, skin and liver were consistently negative. PCR was negative in the skin and liver of all control frogs (Fig. 2).

PCR for ranavirus DNA was positive in the faeces of 3/15 frogs (7, 8 and 11 days p.i.; 3–4.5 days before death) and in the skin sheds of 4/15 frogs (3, 4, 10 and 10 days p.i.; strongly positive 0–1.5 days prior to death) that died from FV3 infection (Table 1). Collectively, 18 faeces and six skin sheds collected on 1–10 days p.i. from several of the 15 dead frogs yielded a negative PCR signal. All faeces and skin sheds collected pre-inoculation and 0–22 days p.i. from control frogs and inoculated frogs that did not develop severe clinical signs to warrant euthanasia were negative.

Gross lesions noted at necropsy were present only in fatally infected frogs and consisted of petechial/ecchymotic haemorrhages in skin (Fig. 1a, b), free blood in oral cavity, focal to extensive haemorrhage in the wall of stomach and/or intestine (Fig. 1c), blood in faecal swab, petechiae in coelomic fat bodies or testicles and an air-filled stomach. Splenomegaly, subjectively determined in reference to the size of the spleen of control frogs, was noted both in fatally infected frogs and those that survived, but it was slightly more marked in mortalities (average 1.9 times larger than control) (Table 1, Fig. 3) than in survivors (average 1.4 times larger than control). Histological lesions were also restricted to fatally infected frogs and involved multiple tissues (Table 2, Figs 4 and 5). Amongst the frogs that survived to the end of the trial there was some evidence of

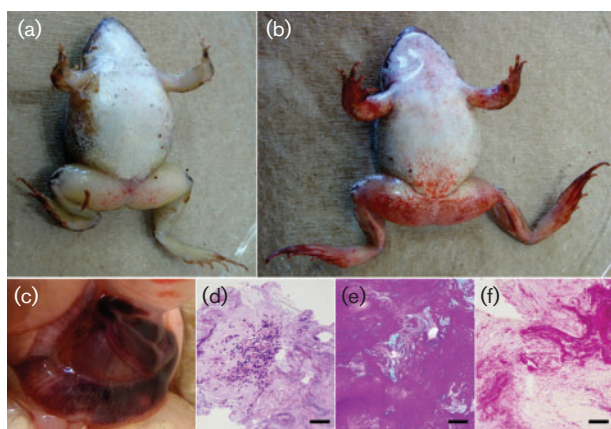


Fig. 1. Gross lesions due to FV3 infection in adult wood frogs. Petechiae in the skin of ventrum and limbs (a, b) and severe haemorrhage in the intestinal wall (c). Histological appearance of mucous bead produced by fatally infected frogs: clusters of cells (haematoxylin & eosin stain, d) surrounded by protein-rich mucus (Periodic Acid-Schiff stain, e) and myriads of Gram-negative bacterial rods (Gram stain, f). Bars, 50 μ m.


















































Dose (p.f.u. per frog)											Mortality (%)											
											ST ₅₀	SV										
10 ^{5.43}												100										
	11.5	33	d	++	10	29	d	++	12	33	e	++	11.5	31	d	++	11.5	34	d	++	11.3	32
10 ^{4.43}												100										
	11	34	d	++	12	30	d	++	14	36	e	++	10	34	d	++	11	30	d	++	11	32.8
10 ^{3.43}												80										
	12	32	e	++	13	36	e	++	13	37	e	++	14	34	e	++	22	39	s	--	13	34.8/39
10 ^{2.43}												20										
	14	31	d	++	22	41	s	--	22	38	s	--	22	32	s	--	22	38	s	--	14	31/37.2
10 ^{1.43}												0										
	22	36	s	--	22	42	s	--	22	34	s	--	22	29	s	--	22	31	s	--	n/a	34.4
10 ^{0.43}												0										
	22	36	s	--	22	35	s	--	22	38	s	--	22	39	s	--	22	36	s	--	n/a	36.8
Control												0										
	22	41	s	--	22	36	s	--	22	38	s	--	22	38	s	--					n/a	38

Fig. 2. Mortalities (black) used to calculate the LD₅₀ of FV3 inoculated orally to adult wood frogs. Below each frog, from left to right: day of death p.i., snout-vent length [SV (mm)], euthanasia due to severe disease, natural death or survival until end of trial (indicated e, d or s, respectively), and PCR for ranavirus DNA in skin and liver (+, -). Right column: percentage of mortality, median survival time [ST₅₀ (days)] and mean size [SV (mm)] of mortalities/survivors per group. n/a, Not applicable.

hyperplasia of haematopoietic tissue in the bone marrow and spleen, renal tubular regeneration or hyperplasia and nodular proliferation of lymphocytes in the wall of the urinary bladder and colonic submucosa. Immunohistochemical staining was performed in one frog from the non-exposed (control) group, two frogs in the group that received the highest dose (10^{5.43} p.f.u.), the sole survivor in the group that received 10^{3.43} p.f.u. dose and three frogs that survived, one from each of the lowest dose groups (10^{2.43}, 10^{1.43} and 10^{0.43} p.f.u.) (Table 3). Immunohistochemical staining for ranaviral antigen (cytoplasmic, usually as fine to coarse variably abundant granules) of the fatally infected frogs that received the highest dose demonstrated the presence of ranavirus antigen in and around areas of necrosis in various tissues (Table 3). In the frogs that survived, staining was observed in scattered single cells in the connective tissue of one or more tissues (Table 3). The morphology of the immunohistochemically stained cells found in survivors, and their location (rarely in parenchymal organs like kidney or pancreas and commonly in the submucosa of a luminal organ or wall of a cavity), suggest tissue macrophages. In nervous tissue (brain and peripheral nerves), testes, ovary, oviduct and abdominal adipose tissue no staining was detected in any

of the frogs. None of the tissues from the non-exposed (control) frog stained immunohistochemically. Non-specific staining was negligible according to the antibody and conjugate internal controls.

DISCUSSION

Our results indicate that the oral LD₅₀ of FV3 in 1-year-old wood frogs averaging 35 mm of SV length is 10^{2.93} (2.42–3.44) p.f.u. per frog. Although wood frogs usually begin reproduction at 2 years of age (Duellman & Trueb, 1994) and our experimental subjects were only 1 year old, most were sexually mature (oogenesis or spermatogenesis evident histologically in 19/20 frogs examined) and thus representative of the anatomy and immunophysiology of adult individuals. Our findings can probably also apply to post-metamorphic juveniles as immune system maturation occurs at metamorphosis or soon afterwards (Robert & Ohta, 2009). Extrapolations to other experimental or to natural infections should be made cautiously if environmental conditions are different from those reported here since habitat characteristics, particularly temperature, are known to influence the immune function of amphibians

Table 1. First appearance of clinical signs, death, interval from first signs to death (ClS–Dth), presence of ranavirus DNA (PCR) in faeces and skin sheds and gross lesions at necropsy of 15 wood frogs that died or were euthanized following oral inoculation with FV3

FV3 (p.f.u.)	Frog	Clinical signs (days p.i.)						Death (days p.i.)*	ClS– Dth†	PCR (days p.i.)				Gross lesions						
		Rgt	Brb	MDpr	SDpr	Ptc	Onst			Faeces		Skin shed		PH-S	B-Or	PH-GI	B-Fc	PH-V	AFS	Splx
										–	+	–	+							
10 ^{5.43}	1		10	11	10		10	11.5	1.5	4, 6, 7									2	
	2			8	10	10	8	10	2	6			y	y	y				2	
	3				12	12	12	12	0	2	8	4	y		y				3	
	4			6, 11		11.5	6	11.5	4.5				y		y	y			1	
	5					11.5	11.5	11.5	0	4	7		y		y			y	1	
10 ^{4.43}	6		10		11	11	10	11	1			10	y				y ^a	y	1.5	
	7					12	12	12	0	4		9	y						2	
	8			13	14	14	13	14	1	1, 6, 7, 9, 10		4	y						2.5	
	9	10			10	10	10	10	0	1, 6		4	10					y	2	
	10			10	11	11	10	11	1	1		3‡	y		y				2	
10 ^{3.43}	11					12	12	12	0				y					y	1	
	12		11, 13		13	13	11	13	2	6		4‡	y		y			y	NR	
	13			13	13	13	13	13	0				y				y ^b	y	2.5	
	14				14	14	14	14	0	7	11		y		y				2.5	
10 ^{2.43}	16	11	13	13		13	11	14	3	2		5	y				y ^a	y	2	

Rgt, Regurgitation of food item; Brb, bacteria-rich mucous bead in water dish; MDpr, dazed stare or mild depression; SDpr, severe depression with loss of withdrawal or righting reflex; Ptc, petechiae in the ventral skin and/or limbs; Onst, first onset of clinical signs; PH-S, petechiae/haemorrhage in skin; B-Or, blood from oral cavity; PH-GI, petechiae/haemorrhage in wall of gastrointestinal tract; B-Fc, blood in faecal swab; PH-V, petechiae/haemorrhage in parenchymatous organs (a, fat bodies; b, testicles); AFS, air-filled stomach; Splx, proportional increase in size of spleen compared with age-matched control; NR, not recorded.

*Death was recorded at time of observation except when a frog died overnight, in which case 0.5 of a day was deducted.

†Interval between onset of clinical signs and time of death (ClS–Dth) of 0 indicates no signs detected on the previous check (<12 h earlier).

‡Indicates only weak positivity in PCR test for ranavirus DNA.

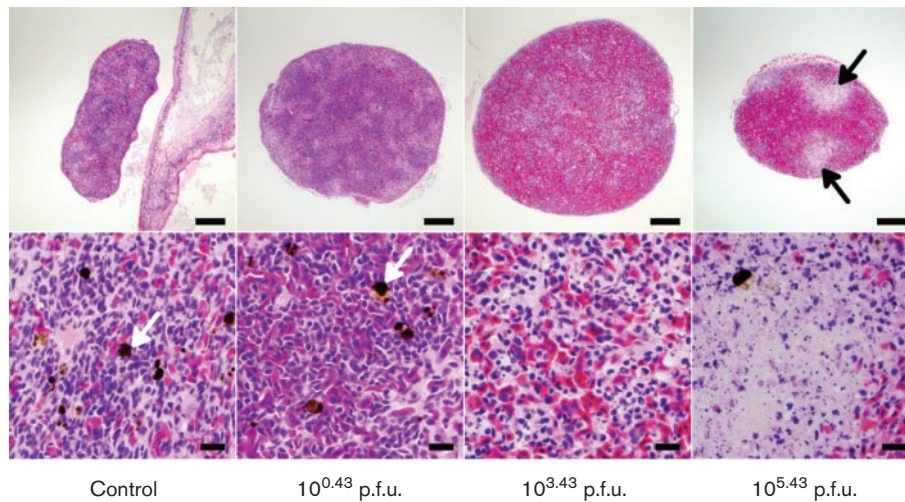


Fig. 3. Lesions associated with oral inoculation with FV3 in the spleen of adult wood frogs shown at subgross (upper row, 40 \times) and histological (bottom row, 400 \times) magnifications. Splens from control and lowest dose frogs (survivors) have no lesions and prominent melanomacrophages (white arrows). Haemorrhage, multifocal necrosis (black arrows) and loss of melanomacrophages increase in proportion to the viral dose received. Haematoxylin & eosin stain. Bars, 200 μ m (top row) or 20 μ m (bottom row).

(Maniero & Carey, 1997). Although we conducted the experimental inoculation in early spring, a time when wood frogs are most likely to come in contact with infected carriers as they go to the ponds for mating (Brunner *et al.*, 2004), the temperature maintained during the experiment (average 21 $^{\circ}$ C) was higher than the environmental temperature would have been in the wild. Statistical models of disease

incorporating any of our results as parameters must account for temperature and humidity differences in the habitat of the population of interest.

Based on our statistical model, dose of FV3 was the most important factor in the length of the incubation period, the survival time and the probability of dying. The odds of dying increased by 23-fold and both clinical signs and

Table 2. Histological lesions in a subset (9/15) of wood frogs that died or were euthanized due to oral inoculation with FV3

FV3 (p.f.u.)	Frog	Skin		Digestive tract/coelom				Bone marrow	Kidney			Urinary bladder	Spleen	Liver
		DH	EpdN	EpN-Or	SH	EpN-GI	H-Ad	HN	HN	GN	TD/N	EpN-Ur	HN	HN
$10^{5.43}$	1			y*		y		y	y	y	y*	y	y	y
	2			y	y	y	y	y*	y	y	y*	y	y	y
	3	y	y	y*			y	y	y	y	y*	y	y	y
$10^{4.43}$	6			y*	y	y	y	y	y		y*	NR	y	
	8		y	y		y		y*	y	y	y*	y*	y	y
	10	y					y	y	y	y		y	y	
$10^{3.43}$	12	y						y	y	y			y	y
	13	y		y	y	y		y	y	y		y*	y	y
$10^{2.43}$	16	y		y		y		y	y	y		y*	NR	y
Overall†	(%)	56	22	78(33*)	33	67	44	100	89	89	56(56*)	88(43*)	100	78

DH, Dermal haemorrhage; EpdN, epidermal necrosis; EpN-Or, epithelial necrosis in oral mucosa and/or tongue; SH, submucosal haemorrhage in gastrointestinal tract; EpN-GI, epithelial necrosis in stomach and/or intestine; H-Ad, haemorrhage in coelomic adipose tissue; HN, haematopoietic necrosis; GN, glomerular necrosis; TD/N, renal tubular degeneration or necrosis; EpN-Ur, epithelial necrosis in urinary bladder; NR, not recorded, tissue lost during processing; y, lesion is present; blank space, lesion is absent.

*Probable viral inclusion bodies present.

†Proportion of frogs with a lesion out of all those examined ($n=9$).

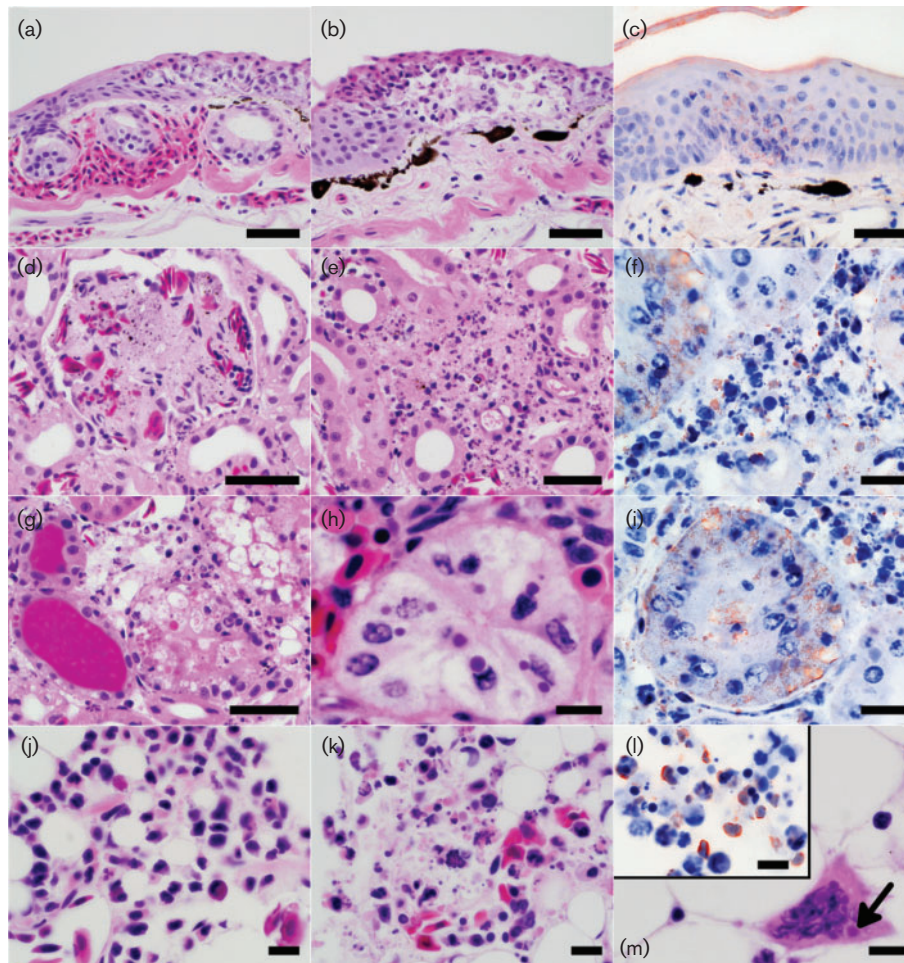


Fig. 4. Lesions associated with oral inoculation with FV3 in adult wood frogs. Dermal haemorrhage (a) and epidermal necrosis (b) in skin of limbs. Renal glomerular (d), haematopoietic (e) and tubular necrosis (g) with occasional intraepithelial intracytoplasmic inclusion bodies (h). Haematopoietic necrosis in the bone marrow of an infected frog (k) is presented adjacent to the bone marrow from a healthy frog (control, j); multinucleated cell with eosinophilic intracytoplasmic inclusions suggestive of viral inclusion bodies (m, arrow). Immunohistochemical staining of skin (c), renal interstitial haematopoietic tissue (f), a renal tubule (i), and bone marrow (l) demonstrates presence of FV3 in lesions. Bars, 50 μ m (a–e, g), 20 μ m (f, i) and 10 μ m (h, j–m).

death occurred approximately 15% sooner per tenfold increase in dose. The lone survivor amongst the frogs that received a dose above the LD_{50} was the largest of its group, while the frog that died in the group given a dose below the LD_{50} was the smallest (Fig. 2). This is probably a reflection of the crudeness of the estimate (both mortalities fall within the 95% CI for the LD_{50} dose) and the inherent variability in susceptibility of live animals to infection more than an indication that the size of the frog, as estimated by SV length, could exert an influence on survivability at a given viral concentration.

While there is no analytical or empirical evidence to support an influence of size on the probability of dying from a given dose of FV3, the incubation period and survival time may be lengthened slightly the larger the frog is. At a given dose, the onsets of clinical signs and death were delayed by approximately 6% and 5%, respectively, for each

millimetre increase in size. Although the model supporting this finding is analytically strong and reflects what was observed in this trial, its predictive potential is very poor, particularly when applied to frogs outside the range of sizes included in this trial. For instance, the model predicts that a 51 mm frog would die 31 days p.i. if given $10^{4.43}$ p.f.u. of FV3 but, based on infection of adult wood frogs of that size (unpublished data), this overestimates the ST_{50} by 17–18 days, incorrectly doubling it. The poor predictive ability could be due to our small sample size or the occurrence of the observations for both events (clinical onset and death) during such a short time interval. The observed effect of size on the ST_{50} and onset of clinical signs is probably an indirect reflection of the effect of dose: when a given dose is administered to two frogs of different sizes, the larger frog necessarily receives a smaller dose proportionally to its body size. This association suggests the need to distinguish

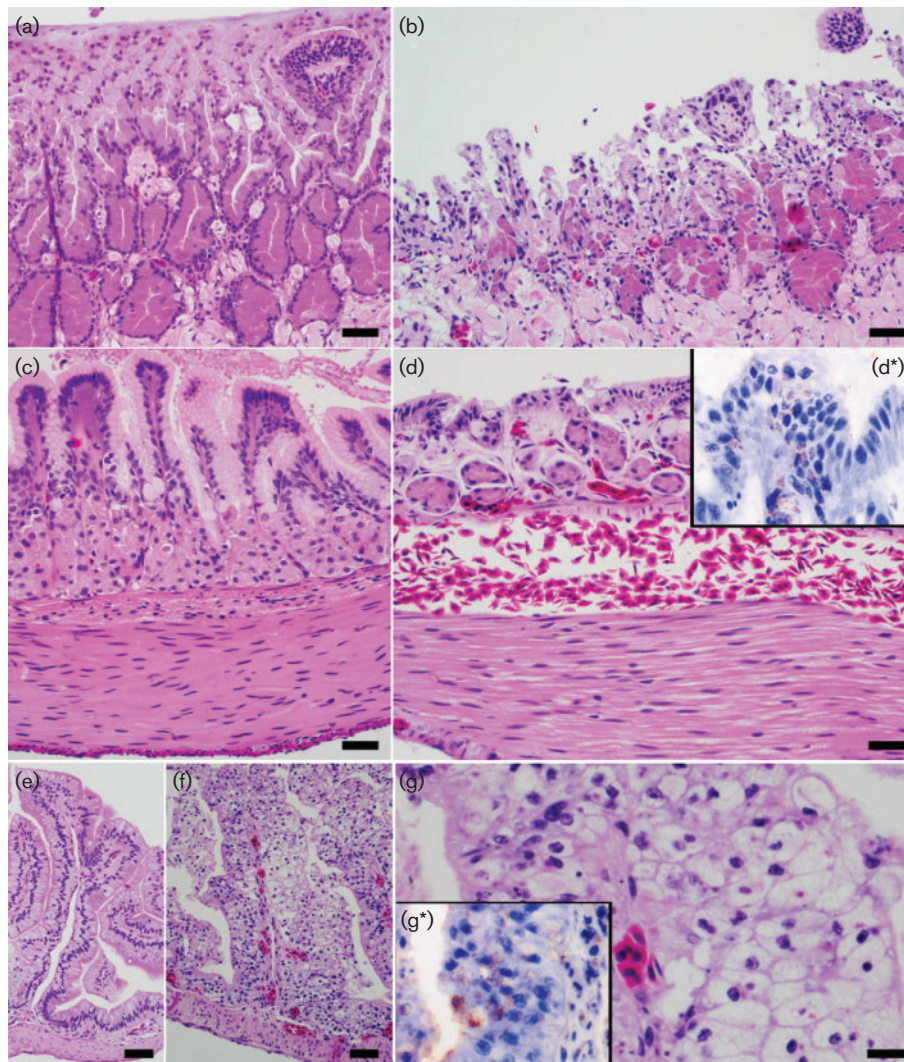


Fig. 5. Lesions associated with oral inoculation with FV3 in adult wood frogs (continued). Sections of tongue (a), stomach (c) and colon (e) from a healthy wood frog (control) present for comparison. Severe epithelial necrosis and erosion of the tongue (b), submucosal haemorrhage in the stomach (d) and severe epithelial degeneration and necrosis with occasional probable intracytoplasmic inclusion bodies in the colon (f–g). Immunohistochemical staining of areas of mucosal epithelial degeneration and necrosis (inserts d* and g*) demonstrates the presence of FV3. Bars, 50 µm (a–f) or 20 µm (g).

between an absolute dose (p.f.u. in inoculum per frog) and a proportional dose (p.f.u. in inoculum mm⁻¹ body size). Based on a logistic regression of our results, the proportional dose of FV3 in adult wood frogs would be calculated as 10^{0.08} p.f.u. mm⁻¹; e.g. the LD₅₀ for a group of wood frogs averaging 50 mm in length would be close to 10^{4.18} p.f.u. per frog. Future experimental infections will be required to test this hypothesis.

While the skin and liver of all frogs that died were positive for ranavirus DNA by PCR, tissues from all surviving frogs were negative. Although this could suggest that infection simply failed to establish in the surviving frogs, the difference in sampling times must be taken into account: 10–

14 days p.i. for mortalities (positive frogs) and 22 days p.i. for survivors (negative frogs). The virus could either have been cleared by the time the survivors were sampled, indicating complete recovery with no carrier state, or simply been present in tissues other than those tested. This corresponds to what occurs in *X. laevis* frogs inoculated intraperitoneally with FV3 where the virus is undetectable in most tissues within 2 weeks of infection (Gantress *et al.*, 2003) and in the kidney 20 days p.i. (Robert *et al.*, 2007) and resembles the negative PCR results found in the liver and blood of wild adult green frogs [*Rana (Lithobates) clamitans*] during a natural outbreak of FV3 (Forzán & Wood, 2013). The immunohistochemical staining observed in cells in various tissues from surviving frogs, even in a

Table 3. Immunohistochemical staining in a subset of wood frogs, *Rana sylvatica* (*Lithobates sylvaticus*), inoculated orally with various doses of FV3 and one non-exposed (control) frog

The primary antibody used (anti-EHNV, epizootic haematopoietic necrosis virus) cross-reacts with FV3 (Ariel *et al.*, 2010). Staining (+) was found in areas of necrosis in frogs that died from the infection (d), or as scattered single cells in connective tissue with no lesions in frogs that survived (s) and were euthanized at 22 days p.i.

	FV3 (p.f.u.)					
	$10^{5.43}$ (d)	$10^{3.43}$ (s)	$10^{2.43}$ (s)	$10^{1.43}$ (s)	$10^{0.43}$ (s)	0 (control)
	n=2	n=1	n=1	n=1	n=1	n=1
Oral/nasal mucosae	+	+	–	+	–	–
Tongue	+	+	–	–	+	–
Epidermis/dermis	+	–	–	–	–	–
Bone marrow	+	–	–	–	–	–
Heart (epicardium)	+	NE	–	–	+	–
Lung	+	–	+	–	–	–
Kidney	+	–	+	–	–	–
Urinary bladder	+	–	+	–	–	–
Liver	+	–	–	–	–	–
Pancreas	+	NE	+	–	–	–
Stomach	+	–	–	–	–	–
Small intestine	+	–	–	–	–	–
Colon	+	–	–	–	–	–
Spleen	+	–	+	–	–	–

NE, Not examined.

frog inoculated with the lowest dose, indicates that the frogs were infected but managed to control the infection and thus survived. The morphology of the immunohistochemically stained cells and their location are suggestive of tissue macrophages. The identity of these cells, whether the material is viable virus or simply segments of viral particles, how long the antigen remains in the surviving host cells (if indeed infected) and what role it plays in transmission is beyond the scope of this study, but the presence of ranavirus antigen in survivors suggests that even low doses of the virus are capable of causing an infection and that recovered animals may serve as asymptomatic carriers.

As stated before, differences in experimental designs of previous studies make comparisons and extrapolations difficult. For instance, *X. laevis* inoculated intraperitoneally with $10^{7.7}$ p.f.u. of FV3 exhibited temporary signs of illness (anorexia, skin shedding and cutaneous erythema of the legs) during the first week p.i. (Gantress *et al.*, 2003). Although the erythema recorded for *X. laevis* may correspond to the petechiation observed in wood frogs in our study, it is impossible to compare the time to onset of clinical signs as the dates provided by Gantress *et al.* (2003) are imprecise. Regarding ST_{50} , mortality of Cope's grey tree frog tadpoles [*Hyla chrysoscelis*, family Hylidae, found in the south-eastern United States (Dodd, 2013)] exposed to water containing FV3 began 12 days p.i. and reached 66% (Hoverman *et al.*, 2010), whereas mortality of tiger salamander tadpoles [*Ambystoma tigrinum*, family Ambysto-

matidae, found in southern Canada, the continental USA and north-eastern Mexico (Duellman & Trueb, 1994)] also exposed to water containing FV3 began just under 20 days p.i. and reached 91% (Brunner *et al.*, 2005). Although these results could suggest a difference in susceptibility between species, Cope's grey tree frogs were exposed to 10^3 p.f.u. ml⁻¹ (10^6 p.f.u. l⁻¹) for 3–21 days whereas salamanders were exposed to 10^5 p.f.u. ml⁻¹ for 7 days. The differences in methodology make it impossible to determine whether time to death and mortality rate are due to inherent species differences or simply reflect a different infective dose. If the method of Reed & Muench (1938) is applied to the salamander data as reported by Brunner *et al.* (2005) (Table 1), the LD_{50} of FV3 equals $10^{3.05}$ p.f.u. ml⁻¹: a dose very close to the concentration of FV3 that caused 66% mortalities in Cope's grey tree frogs. Hoverman *et al.* (2010), by using a consistent methodology, demonstrated that tadpoles of three different species [pickerel frog, *Rana (Lithobates) palustris*, Cope's grey tree frog, and eastern narrow-mouthed toad, *Gastrophryne carolinensis*] are not equally susceptible to mortality when exposed to FV3. The authors also concluded that oral inoculation of a known dose of FV3 (10^6 p.f.u.) both increased mean mortality rate and sped time to death when compared to water-bath exposure. However, as the same viral concentration used in the direct oral infection was diluted in a 1 l water bath, the different outcomes may actually reflect the effect of dose, not of route of infection (Hoverman *et al.*, 2010).

The use of oral dosing, as opposed to the often used intraperitoneal injection, is a better approximation of what occurs under natural conditions (Gray *et al.*, 2009). Exposure to virus-loaded water is thought to achieve infection via contact with oral or branchial mucosa (Gray *et al.*, 2009). Therefore, oral administration may be just as relevant in replicating natural exposure to viral particles in water bodies as is immersion in a water bath, and possibly more relevant for terrestrial species like the wood frog. Oral dosing allows for administration of relatively precise doses, and can be effected easily in most post-metamorphic frogs and even tadpoles of some species (Wolf *et al.*, 1968; Hoverman *et al.*, 2010).

The positive PCR signal (ranavirus DNA) in faeces and skin sheds of frogs that died from infection suggests that both are potential sources of transmission, particularly in the last few days before death.

Gross and histological lesions present in frogs that died from FV3 infection resembled those reported in most other species infected with a *Ranavirus* sp. (Gray *et al.*, 2009; Cullen & Owens, 2002; Cunningham *et al.*, 2007; Kik *et al.*, 2011) and involved primarily the haematopoietic cells (bone marrow, spleen, kidney and liver), renal glomeruli, and mucosal epithelium of the oral cavity, gastrointestinal tract and, to a lesser degree, urinary bladder. Necrosis of the colonic mucosa seemed to have been associated with an accumulation of mucus and bacterial overgrowth in the colon of some individuals, which was shed as a cohesive pearly white mass approximately 24 h prior to death. Whereas the main lesion reported in immunocompromised *X. laevis* infected with FV3 was necrosis of the epithelium of renal proximal tubules (Robert *et al.*, 2005), damage to the epithelium of the renal tubules in wood frogs was observed only in some individuals and it was often mild. Although there may be a true difference in the type of tissue targeted by FV3 in each species, the published histopathological images of FV3 infection in *X. laevis* appear to represent haematopoietic rather than tubular necrosis (Robert *et al.*, 2005). In some of the frogs that survived the infection, and particularly in the one survivor of the group that received $10^{3.43}$ p.f.u. of FV3, there appeared to have been hyperplasia of bone marrow haematopoietic tissue, regeneration of renal tubules and formation of small clusters of lymphocytes in the colonic and urinary bladder mucosa, suggesting an activation of the immune system during infection. Supporting this interpretation is the lymphocytic (CD8) response to FV3 that occurs in *X. laevis* (Morales & Robert, 2007), but the precise mechanism of this response in wood frogs require further investigation.

The development and characterization of this ranavirus-wood frog model is an important step to facilitate research of ranavirus infection in North American frogs. Oral inoculation, developed for this study, was easily performed and allowed for the administration of precise doses. Our results include environmental parameters, clinical signs, median survival time, probability of death at a given dose, viral shedding in faeces and skin sheds, gross and histological lesions and immunohistochemical staining results under

controlled laboratory conditions. These findings provide transmission, infection and mortality estimates that could be incorporated into ranavirus disease models and facilitate the design of experiments to investigate the pathogenesis of ranavirus infection in North American frogs.

METHODS

Origin and housing of experimental subjects. Wood frog tadpoles were collected from an urban pond in Prince Edward Island, Canada, 1–2 weeks after hatching (17 May 2012) and housed in accordance with guidelines of the Canadian Council on Animal Care (CCAC, 2004; Fig. S1a, b). Tadpoles (later frogs) were maintained at a fairly constant room temperature both before and during the experimental infection (overall average 21–22 °C). Humidity varied considerably and reflected the seasonal ambient temperature (overall average 41–56%) (Supplementary Table S1). All mortalities (29/112 frogs that completed metamorphosis) that occurred in the months prior to the experiment were examined grossly and histologically for any lesions suggestive of a ranavirus infection since there is no reliable method to detect subclinical infection in live animals. As none of the mortalities had any histological evidence of a ranaviral infection, we assumed that the captive-raised animals were free of the virus. One year post-hatching (2 May 2013), the 34 frogs used in the experimental trial were placed in individual tanks and randomly assigned to an infection ($n=30$, five frogs per dose of inoculum) or control group ($n=4$). After 6 days of acclimation to their individual tanks, the frogs were inoculated with FV3.

FV3 culture. The virus stock used in this study, originally isolated in 1965 from a Northern leopard frog, *Rana (Lithobates) pipiens* (Granoff *et al.*, 1966), was grown by the authors in EPC (one passage) at room temperature (18–20 °C) (please refer to supplementary Methods). Titrations of viral stock were performed to determine median TCID₅₀ and p.f.u. following standard methods (Reed & Muench, 1938; Dulbecco & Vogt, 1954). Calculation of LD₅₀ dose followed the method of Reed & Muench (1938) corroborated by a logistic regression.

Inoculation, termination and sample collection. On inoculation day, each frog was orally administered 50 µl of minimum maintenance medium (MEM supplemented with 2% FBS and 1% Antibiotic Antimycotic, Invitrogen) containing 0 (control group, $n=4$), $10^{0.43}$, $10^{1.43}$, $10^{2.43}$, $10^{3.43}$, $10^{4.43}$ or $10^{5.43}$ p.f.u. of FV3 (infection groups, $n=5$ per dose of inoculum) through a graded pipette (Fig. S1c). The small volume of inoculum was chosen to avoid any regurgitation. Frogs were checked two or three times daily to record specific clinical signs. Faeces and skin sheds found in the water dish of control and inoculated frogs were collected opportunistically, frozen at –80 °C and later tested for ranavirus DNA by PCR. Upon every collection the water dish was disinfected and refilled with clean water. All handling started with the controls and continued through the infection groups from lowest to highest virus dose; equipment (i.e. plastic gloves, metal forceps) was disinfected with sodium hypochlorite (5% bleach solution) after handling each frog or enclosure.

Euthanasia was performed at a predetermined end point [when frogs exhibited signs indicative of serious illness (Wright & Whitaker, 2001) that would have eventually resulted in death] instead of allowing death to occur naturally. Thus, euthanasia (by immersion in a 10% solution of tricaine methanesulfonate, TMS; Syndel Laboratories) was performed when a frog exhibited two or more of the following signs: severely depressed appearance (head down and back legs extended with loss of normal upright posture and of withdrawal reflex), loss of righting reflex or presence of many petechial haemorrhages in the skin of the fore or hind feet, inner thighs or ventrum (Fig. 1a, b). The

experiment was terminated 22 days p.i., 8 days after the last mortality occurred, by euthanizing all remaining frogs. Previous studies have considered 21 days p.i. sufficient for infection and morbidity due to ranavirus to occur (Hoverman *et al.*, 2011). Immediately after death the snout-vent (SV) length was measured, a necropsy performed and gross lesions recorded. Weight, being extremely variable due to hydration status, food in the stomach and urine in the bladder (Wright & Whitaker, 2001), was intentionally not recorded. Samples of ventral skin and left liver lobe were collected, frozen at -80°C and later tested for ranavirus DNA by PCR. The rest of the carcass was preserved in 10% buffered formalin. The formalin-fixed carcasses of three frogs from each dose group and two control frogs were processed routinely for histological examination (10 months post-fixation). Tissues, sectioned at 5 μm and stained with haematoxylin and eosin, included one fore foot, one hind foot, a median section of the head and jaw, a cross mid-shaft section of the thigh, and sections of heart, lungs, abdominal fat body, liver, kidneys, urinary bladder, stomach, intestine, colon, spleen and reproductive organs. All procedures followed a protocol approved by the Animal Care Committee of the University of Prince Edward Island.

Immunohistochemical staining. A subset of the tissues examined histologically was stained immunohistochemically using a primary antibody known to cross-react with FV3 (Ariel *et al.*, 2010) to detect the presence of viral particles. Briefly, 5 μm sections were deparaffinised by immersion in two separate baths of xylene (3 min each), three separate baths of 100% ethanol (2 min each) and rinsed in running tap water (1 min). After antigen epitope retrieval was achieved by boiling in TE (Tris/EDTA pH 8.5) solution for 20 min using an 850 W microwave, the slides were washed with tap water, carefully dried and a well was created around the tissue sections to hold the immunohistochemical solutions. Slides were washed three times with TE, blocked with ELISA buffer containing casein (30 min at room temperature) and incubated (1.5 h at room temperature) with 50 μl of rabbit anti-Bohle Iridovirus antibody diluted 1:1 in TE. Slides were then washed three times with TE, incubated in a solution of 0.3% hydrogen peroxide and 0.1% sodium azide in TE (15 min) to inactivate endogenous peroxidase, washed three more times with TE and incubated (1.5 h at room temperature) with 50 μl of goat anti-rabbit-HRP conjugate antibody diluted in TE with 1% BSA. Following another three washes with TE, the slides were developed with the addition of 100 μl of the chromogenic solution (0.005% 3-amino-9-ethylcarbazole and 0.001% hydrogen peroxide in substrate buffer, 20 min at room temperature), then rinsed in running tap water, counter stained with haematoxylin (5 min) and rinsed again with tap water. Once dried, coverslips were placed on the slides using an aqueous mounting medium. Non-specific binding and endogenous peroxidase control slides were produced by omitting the primary antibody and conjugated antibody, respectively, from the protocol described above (Fig. S3).

PCR for FV3 DNA. Skin and liver samples were individually transferred into tissue lysis buffer, total DNA was extracted using a spin-column DNA purification procedure (Qiagen DNeasy 96) and tested for the ranavirus major capsid protein gene with single round PCR amplification (Mao *et al.*, 1997), using the primers covering the same region of the MCP gene as the MCP1 assay recommended by the Aquatic Animal Health Code (5'-GACTTGGCCACTTATGAC-3' and 5'-GTCTCTGGAGAAGAAGAA-3') (World Organisation for Animal Health, 2012). For the faecal samples, lysis buffer was added into the sample tubes and vortexed at 55°C four times within 1 h, then transferred to newly labelled microfuge tubes for DNA extraction.

Parameter calculation and statistical analysis. We calculated median time to onset of clinical signs and median time to death (synonym: ST_{50}), and assessed the influence of inoculum dose and body size (SV length) on: onset of clinical signs and ST_{50} (time ratios, TRs), probability of infection and probability of death (odds ratio,

OR). Infection was defined as positive PCR amplification from DNA extracted from a skin or liver sample. TRs were calculated using parametric survival models with a log-logistic distribution including only groups where clinical signs or deaths occurred. ORs were calculated using a logistic regression. Analysis was performed on STATA 13.1 (Stata statistical software, Stata Corporation LP).

ACKNOWLEDGEMENTS

This work was partly funded by the Alexander Graham Bell Graduate Scholarship-Doctoral and the Canadian Cooperative Wildlife Health Centre (now Canadian Wildlife Health Cooperative). The authors thank Dr Alexandra Reid, who kindly provided the isolate of FV3 used in the infection, Drs Marion Desmarchelier, Shannon Martinson and Jonathan Spears, Mr Chris MacQuaid and Maciez Zawadzki, and in particular Dr Jessica Thompson and Ms Sara Vazquez Quiroga, whose efforts were indispensable to the successful rearing of the wood frogs.

REFERENCES

- Ariel, E., Holopainen, R., Olesen, N. J. & Tapiovaara, H. (2010). Comparative study of ranavirus isolates from cod (*Gadus morhua*) and turbot (*Psetta maxima*) with reference to other ranaviruses. *Arch Virol* **155**, 1261–1271.
- Brunner, J. L., Schock, D. M., Davidson, E. W. & Collins, J. P. (2004). Intraspecific reservoirs: complex life history and the persistence of a lethal ranavirus. *Ecology* **85**, 560–566.
- Brunner, J. L., Richards, K. & Collins, J. P. (2005). Dose and host characteristics influence virulence of ranavirus infections. *Oecologia* **144**, 399–406.
- CCAC (2004). Canadian Council on Animal Care Species-specific Recommendations on: Amphibians and Reptiles. http://www.cac.ca/Documents/Standards/Guidelines/Add_PDFs/Wildlife_Amphibians_Reptiles.pdf
- Chinchar, V. G. (2002). Ranaviruses (family *Iridoviridae*): emerging cold-blooded killers. *Arch Virol* **147**, 447–470.
- Chinchar, V. G., Hyatt, A., Miyazaki, T. & Williams, T. (2009). Family Iridoviridae: poor viral relations no longer. In *Current Topics in Microbiology and Immunology*, vol. 328, pp. 123–170. Edited by J. L. Van Etten. Berlin: Springer-Verlag.
- Cullen, B. R. & Owens, L. (2002). Experimental challenge and clinical cases of Bohle iridovirus (BIV) in native Australian anurans. *Dis Aquat Organ* **49**, 83–92.
- Cunningham, A. A., Hyatt, A. D., Russell, P. & Bennett, P. M. (2007). Emerging epidemic diseases of frogs in Britain are dependent on the source of ranavirus agent and the route of exposure. *Epidemiol Infect* **135**, 1200–1212.
- Dodd, C. K. (2013). *Frogs of the United States and Canada*, pp. 250–262. Baltimore, MD: The Johns Hopkins University Press.
- Duellman, W. E. & Trueb, L. (1994). *Biology of Amphibians*, 2nd edn, pp. 37, 497, 505, 520–522, 542–544. Baltimore, MD: The Johns Hopkins University Press.
- Dulbecco, R. & Vogt, M. (1954). Plaque formation and isolation of pure lines with poliomyelitis viruses. *J Exp Med* **99**, 167–182.
- Forzán, M. J. & Wood, J. (2013). Low detection of ranavirus DNA in wild postmetamorphic green frogs, *Rana (Lithobates) clamitans*, despite previous or concurrent tadpole mortality. *J Wildl Dis* **49**, 879–886.
- Gantress, J., Maniero, G. D., Cohen, N. & Robert, J. (2003). Development and characterization of a model system to study amphibian immune responses to iridoviruses. *Virology* **311**, 254–262.

- Granoff, A., Came, P. E. & Breeze, D. C. (1966).** Viruses and renal carcinoma of *Rana pipiens*. I. The isolation and properties of virus from normal and tumor tissue. *Virology* **29**, 133–148.
- Gray, M. J., Miller, D. L. & Hoverman, J. T. (2009).** Ecology and pathology of amphibian ranaviruses. *Dis Aquat Organ* **87**, 243–266.
- Harp, E. M. & Petranka, J. W. (2006).** Ranavirus in wood frogs (*Rana sylvatica*): potential sources of transmission within and between ponds. *J Wildl Dis* **42**, 307–318.
- Hoverman, J. T., Gray, M. J. & Miller, D. L. (2010).** Anuran susceptibilities to ranaviruses: role of species identity, exposure route, and a novel virus isolate. *Dis Aquat Organ* **89**, 97–107.
- Hoverman, J. T., Gray, M. J., Haislip, N. A. & Miller, D. L. (2011).** Phylogeny, life history, and ecology contribute to differences in amphibian susceptibility to ranaviruses. *EcoHealth* **8**, 301–319.
- Kik, M., Martel, A., Sluijs, A. S., Pasmans, F., Wohlsein, P., Gröne, A. & Rijks, J. M. (2011).** Ranavirus-associated mass mortality in wild amphibians, the Netherlands, 2010: a first report. *Vet J* **190**, 284–286.
- Lesbarrères, D., Balseiro, A., Brunner, J., Chinchar, V. G., Duffus, A., Kerby, J., Miller, D. L., Robert, J., Schock, D. M. & other authors (2012).** Ranavirus: past, present and future. *Biol Lett* **8**, 481–483.
- Maniero, G. D. & Carey, C. (1997).** Changes in selected aspects of immune function in the leopard frog, *Rana pipiens*, associated with exposure to cold. *J Comp Physiol B* **167**, 256–263.
- Mao, J., Hedrick, R. P. & Chinchar, V. G. (1997).** Molecular characterization, sequence analysis, and taxonomic position of newly isolated fish iridoviruses. *Virology* **229**, 212–220.
- Miller, D. L., Gray, M. & Storfer, A. (2011).** Ecopathology of ranaviruses infecting amphibians. *Viruses* **3**, 2351–2373.
- Morales, H. D. & Robert, J. (2007).** Characterization of primary and memory CD8 T-cell responses against ranavirus (FV3) in *Xenopus laevis*. *J Virol* **81**, 2240–2248.
- Reed, L. J. & Muench, H. (1938).** A simple method for estimating fifty percent endpoints. *Am J Hyg* **27**, 493–497.
- Robert, J. & Ohta, Y. (2009).** Comparative and developmental study of the immune system in *Xenopus*. *Dev Dyn* **238**, 1249–1270.
- Robert, J., Morales, H., Buck, W., Cohen, N., Marr, S. & Gantress, J. (2005).** Adaptive immunity and histopathology in frog virus 3-infected *Xenopus*. *Virology* **332**, 667–675.
- Robert, J., Abramowitz, L., Gantress, J. & Morales, H. D. (2007).** *Xenopus laevis*: a possible vector of Ranavirus infection? *J Wildl Dis* **43**, 645–652.
- Robert, J., George, E., De Jesús Andino, F. & Chen, G. (2011).** Waterborne infectivity of the Ranavirus frog virus 3 in *Xenopus laevis*. *Virology* **417**, 410–417.
- Tweedell, K. & Granoff, A. (1968).** Viruses and renal carcinoma of *Rana pipiens*. V. Effect of frog virus 3 on developing frog embryos and larvae. *J Natl Cancer Inst* **40**, 407–410.
- Wolf, K., Bullock, G. L., Dunbar, C. E. & Quimby, M. C. (1968).** Tadpole edema virus: a viscerotropic pathogen for anuran amphibians. *J Infect Dis* **118**, 253–262.
- World Organisation for Animal Health (2012). **Manual of diagnostic tests for aquatic animals.** <http://www.oie.int/en/international-standard-setting/aquatic-manual/access-online/>
- World Organisation for Animal Health (2013). Aquatic Animal Health Code. <http://www.oie.int/en/international-standard-setting/aquatic-code/access-online/>
- Wright, K. M. & Whitaker, B. R. (2001).** *Amphibian Medicine and Captive Husbandry*, pp. 99–101. Malabar, FL: Krieger Publishing Company.