



First Report of a Ranavirus Associated with Morbidity and Mortality in Farmed Chinese Giant Salamanders (*Andrias davidianus*)

Y. Geng^{*,†}, K. Y. Wang^{*,†}, Z. Y. Zhou^{*}, C. W. Li^{*}, J. Wang^{*}, M. He^{*},
Z. Q. Yin^{*} and W. M. Lai^{*}

^{*} College of Veterinary Medicine and [†] Key Laboratory of Animal Disease and Human Health of Sichuan Province, Sichuan Agricultural University, Ya'an, Sichuan 625014, China

Summary

From February to May 2010, an outbreak of disease occurred amongst farmed Chinese giant salamanders (*Andrias davidianus*) in Hanzhong County, Shanxi Province, China. Clinical signs included anorexia, lethargy, ecchymoses and swollen areas on the head and limbs, and skin ulceration. The aim of this study was to determine the cause of this disease. Necropsy examination revealed subcutaneous and intramuscular oedema, swollen and pale livers with multifocal haemorrhage, swollen kidneys with multifocal haemorrhage and distended fluid-filled intestines with areas of haemorrhage. Light microscopy revealed intracytoplasmic inclusions suggestive of a viral infection in a variety of organs, as well as degeneration and necrosis of these organs. Electron microscopy of ultrathin sections of the same tissues revealed iridovirus-like particles within the inclusions. Of the six specimens tested, all were positive for ranavirus major capsid protein (MCP) gene. Sequence alignments of the ranavirus MCP gene from these specimens showed 95–98% similarity with published ranavirus data. The virus, provisionally designated as Chinese giant salamander virus (CGSV), was isolated from tissue homogenates of diseased salamanders following inoculation of epithelioma papilloma cyprini cells. Sequence analysis of the MCP genes showed that the isolated virus was a ranavirus with marked sequence identity to other members of the genus Ranavirus. Koch's postulates were fulfilled by infecting healthy Chinese giant salamanders with the CGSV. These salamanders all died within 6–8 days. This is the first report of ranavirus infection associated with mass mortality in Chinese giant salamanders.

© 2010 Published by Elsevier Ltd.

Keywords: *Andrias davidianus*; Chinese giant salamander; iridovirus; pathology; ranavirus

Introduction

Iridoviruses are large enveloped viruses that contain a linear double stranded DNA genome. The family Iridoviridae currently contains five genera: Iridovirus and Chloriridovirus are associated with insects; Lymphocystivirus and Megalocytivirus infect fish species; and Ranavirus members infect fish, reptiles and amphibians and are associated with clinical illness that ranges in severity from inapparent to fulminant (Williams *et al.*, 2005b). Ranaviruses are receiving increasing attention due to the severe losses they can cause to both wild and farmed fish and amphibian pop-

ulations (Pozet *et al.*, 1992; Cullen and Owens, 2002; Bigarré *et al.*, 2008). Mass mortality of amphibians caused by ranaviruses has been reported in the Americas, Europe and Asia (Ariel *et al.*, 2009; Gray *et al.*, 2009; Une *et al.*, 2009b). The first ranavirus infection in China was reported in an episode of mass deaths of pig frogs (*Rana grylio*) in 2001 (Zhang *et al.*, 2001). There is evidence that ranaviruses may be an emerging infectious disease (Storfer *et al.*, 2007), possibly due to emergence of a novel strain (Picco and Collins, 2008) or increased occurrence of anthropogenic stressors on the landscape (Forson and Storfer, 2006; Gray *et al.*, 2007). Recognizing the potential threat of ranaviruses to global amphibian biodiversity, ranavirus infections have been added to

Correspondence to: Y. Geng (e-mail: gengyisicau@126.com).

the list of 'notifiable' diseases by the World Organization for Animal Health (OIE; http://www.oie.int/eng/maladies/en_classification2010.htm?e1d7). This means that international trade of live amphibians and related products now requires health certification to be applied according to OIE standards, making it obligatory for both the public and the OIE to be notified about the detection of ranavirus infection.

Ranaviruses negatively impact on amphibian populations throughout the world and have been associated with population fluctuations and mass mortality events (Collins and Storfer, 2003; Daszak *et al.*, 2003). Ranaviruses have been identified in tissues obtained from a variety of wild and captive salamander species, including the Sonoran tiger salamander (*Ambystoma tigrinum stebbinsi*) (Jancovich *et al.*, 1997), tiger salamander larvae (*Ambystoma tigrinum diabolii*) (Bollinger *et al.*, 1999), the spotted salamander (*Ambystoma maculatum*) (Douglas *et al.*, 2003), the Japanese clouded salamander (*Hynobius nebulosus*) (Une *et al.*, 2009a) and 10 species of lungless salamanders (such as *Desmognathus conanti*, *Desmognathus imitator*, *Desmognathus monticola*, *Desmognathus quadramaculatus* and *Eurycea wilderae*) (Matthew and Debra, 2009) that died in Canada, the USA and Japan. The Chinese giant salamander (*Andrias davidianus*), which belongs to the order Caudata and family Cryptobranchidae, is the largest extant species of amphibian. There are only three species in this family: the Chinese giant salamander (*A. davidianus*) in China, the Japanese giant salamander (*Andrias japonicus*) in Japan and the hellbender (*Cryptobranchus alleganiensis*) in North America (Regal, 1966). The Chinese giant salamander is classified as critically endangered by the International Union for Conservation of Nature and Natural Resources, is a class II state major protected species in China and is included in Appendix I of the Convention on International Trade in Endangered Species of Wild Fauna and Flora. This species is in peril because of habitat loss, relatively slow growth to sexual maturity (6 years), poaching for human consumption, medicinal use and infectious disease (Wang *et al.*, 2004).

From February to May 2010, an outbreak of an infectious disease occurred in farmed Chinese giant salamanders in Hanzhong County, Shanxi Province, China. Symptoms included skin ulceration, anorexia, lethargy and occasionally oedema, and the mortality rate was high. The Key Laboratory of Animal Disease and Human Health of Sichuan Province performed diagnostic evaluations of this outbreak. Pathological and molecular studies confirmed that the infectious agent was a ranavirus. This is the first report of ranavirus infection associated with mass mortality in Chinese giant salamanders.

Materials and Methods

Sample Collection

From February to May 2010, a disease outbreak occurred in farmed Chinese giant salamanders in Hanzhong County, Shanxi Province, China. Larval, juvenile and adult salamanders were affected. During the outbreak, approximately 350 of 570 salamanders died. Twelve sick salamanders (four larvae, five juveniles and three adults) were collected and transferred alive to the Key Laboratory of Animal Disease and Human Health of Sichuan Province to determine the cause of the disease.

Necropsy Examination

Necropsy examinations were performed on all 12 Chinese giant salamanders. Samples for microscopical examination, including major viscera (liver, lung, heart, kidney, spleen, stomach and intestine), brain and any gross lesions, were collected from all 12 salamanders and fixed in 10% neutral buffered formalin. Formalin-fixed tissues were processed routinely and embedded in paraffin wax. Sections (4 µm) were stained with haematoxylin and eosin (HE).

For electron microscopical examination, selected areas of liver, kidney and spleen from five affected Chinese giant salamanders (two larvae, two juveniles and one adult) were cut into 1 mm³ pieces and fixed in 2% glutaraldehyde in phosphate buffer (pH 7.3, 0.1 M) at 4°C. After post-fixation with 1% osmium tetroxide, the pieces were dehydrated through a series of graded alcohols, embedded in epoxy resin, sectioned at 50 nm, stained with uranyl acetate and lead citrate and observed under a transmission electron microscope (TEM; JEM-1200EX, JEOL, Tokyo, Japan).

Bacteriological Examination

The body surface of each salamander was swabbed with 70% ethanol to prevent contamination. Samples from the kidney, liver, spleen and ascites fluid of each sick salamander were streaked directly onto sheep blood tryptone soy agar (TSA) and inoculated at 30°C. All isolates were identified using the API 20E system (BioMerieux, La Balm, France).

PCR for Ranavirus in Tissues

Tissues (typically lung, liver and spleen) were collected from the remaining carcasses and frozen at -20°C for virus examination. The previous epizootiological and clinical observations suggested that an iridoviral agent may have been the primary cause of the disease. Therefore, a conventional polymerase chain reaction (PCR)

was used to test for the presence of ranavirus. Genomic DNA was extracted from tissues using a commercially available kit (TaKaRa, Dalian, China). DNA from tissues was used as a template and amplified by PCR using primers (forward primer: 5'-GACTTGG CCACTTATGAC-3'; 5'-GTCTCTGGAGAAGAA GAA-3') targeted to highly conserved regions of the major capsid protein (MCP) gene of ranaviruses (FV3) (Mao *et al.*, 1997). These primers were used to obtain an expected fragment size of approximately 500 base pairs (bp). The PCR products were resolved by gel electrophoresis for determination of the presence/absence of ranavirus. Two distinct PCR-positive bands were chosen randomly, cut from the gel and purified with the Gel DNA Purification Kit (TaKaRa). Sequencing of the bands was performed using the 3730 DNA sequencer (Shanghai Invitrogen Biotechnology Co. Ltd., Shanghai, China). The sequence was assembled using DNA Star software and a GenBank BLAST search (<http://www.ncbi.nlm.nih.gov/Genbank.html>) was performed on the sequence to verify that it was a ranavirus.

Virus Isolation and PCR Detection of Ranavirus

Liver and kidney from diseased Chinese giant salamanders were thawed, pooled and homogenized in 2 ml of minimal Eagle's medium (MEM) containing 2% fetal bovine serum (FBS), 750 IU/ml penicillin and 750 µg/ml streptomycin (Sigma Aldrich NV, Bornem, Belgium). The homogenate was centrifuged at 2,000 g for 10 min and the supernatant was filtered through a 0.45 µm filter. A 300 µl sample of the filtrate was inoculated onto epithelioma papulosum cyprini (EPC) cells. The EPC cells, maintained at 20°C in MEM containing 10% FBS, 100 IU/ml penicillin and 100 µg/ml streptomycin, were observed for cytopathic effects (CPE) at regular intervals. The cell monolayer demonstrating CPE was freeze-thawed three times and the mixture was clarified by centrifugation for 10 min at 1,000g at 4°C. The supernatant was stored at -80°C and used as a virus stock for virus passage.

To prepare DNA for PCR analysis, EPC cells incubated with Chinese giant salamander extracts were grown in flasks until 100% CPE was observed. The cultures were then harvested, the cell pellets suspended in 100 mM Tris-HCl (pH 7.5), with 5 mM EDTA, 0.2% sodium dodecyl sulphate, 200 mM NaCl and 0.1 mg/ml proteinase K (400 µl), incubated at 50°C for 2 h, and extracted with phenol-chloroform followed by chloroform. Nucleic acids were precipitated with ethanol and resuspended in 40 µl of water (Sigma-Aldrich). To verify that the isolated virus was a ranavirus, PCR analysis was performed as described above.

Experimental Infection of Chinese Giant Salamanders

In order to test Koch's postulates, EPC-grown Chinese giant salamander virus (CGSV) was used to inoculate five healthy Chinese giant salamanders (body weight 120.0 ± 5.0 g) collected in Sichuan province and housed at the College of Veterinary Medicine (Sichuan Agricultural University, Sichuan, China) for 6 weeks prior to inoculation. The salamanders were inoculated intraperitoneally (IP) with 0.5 ml of stock virus solution containing 5×10^6 plaque forming units (PFU) of CGSV. The salamanders were monitored daily for signs of disease. Following death of the salamanders, necropsy examinations were performed and tissues were collected for histopathology and processed as described above. A homogenate of liver, spleen and kidney from each salamander was used for virus isolation.

Results

Field Observations, Clinical Signs and Gross Pathology

A disease outbreak occurred in farmed Chinese giant salamanders in Hanzhong County, Shanxi Province, China, from February to May 2010. The animals began to die 15 days after the introduction of some newly-collected animals. During the outbreak, approximately 350 of a total of 570 salamanders died.

Clinical signs of disease varied and occasionally animals were found dead without premonitory signs. Sick larvae were lethargic and slow moving. Typical clinical signs included lethargy, slow movement, anorexia, bloody stools, vomiting (occasionally bloody), small pale raised foci in the skin and cutaneous erosions and ulcers (Fig. 1A). Ecchymoses and swollen areas were noted on the head, ventral surface and limbs, and in some cases there was also necrosis of the limbs (Fig. 1B). The skin became dark and speckled and shed skin was fragmented. A few giant salamanders produced thick sticky mucus from the dorsum and tail, which adhered to their skin.

At necropsy examination, the coelomic cavity often contained clear or bloody fluid. Livers were pale and swollen, with multifocal haemorrhages (Fig. 1C). The stomach wall was occasionally oedematous and haemorrhagic. The intestine was thin-walled and mildly distended with clear fluid or blood, and areas of haemorrhage were evident on the serosal surface.

Histopathology and Electron Microscopical Examination

Microscopical examination revealed that the lesions observed in the heart, lung, liver, pancreas, stomach, intestine, spleen, skeletal muscle, gonad, brain and skin were similar to those described previously for

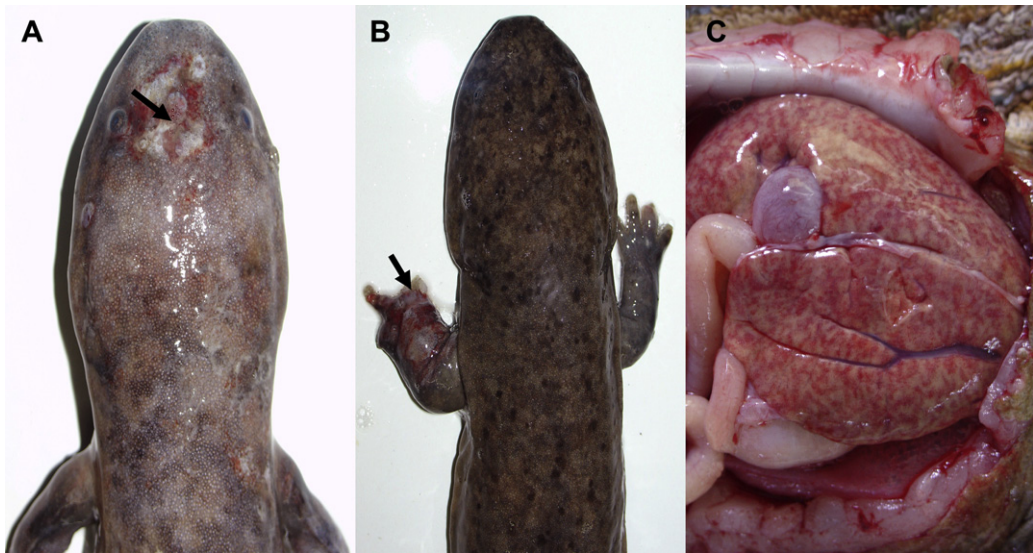


Fig. 1. Gross lesions in an infected Chinese giant salamander. (A) Cutaneous erosions (arrow) and swollen areas on the head. (B) Ecchymoses, swelling and necrosis in a forelimb (arrow). (C) The liver was pale and swollen with multifocal haemorrhages.

tiger salamanders and spot salamanders (Bollinger *et al.*, 1999; Douglas *et al.*, 2003). Severe lesions were noted in the kidney, liver, spleen, skin and gastrointestinal tract. These consisted of scattered single necrotic cells and variably sized foci of multicellular necrosis. Degenerate cells, necrotic cells and cells adjacent to areas of necrosis commonly contained large cytoplasmic inclusions.

Vacuolar degeneration of the renal tubular epithelial cells, focal tubular necrosis and glomerulonephri-

tis were present in the kidney. Inclusions were seen in the renal tubular epithelium (Fig. 2A). Hepatocellular swelling and vacuolar degeneration were common in the liver and there were occasional foci of hepatocyte necrosis. Hepatocytes also frequently contained viral inclusions, which were either associated with single degenerate cells or larger foci of necrosis (Fig. 2B). Granulopoiesis was common in the liver and kidneys. Degeneration, necrosis and sloughing of the epithelium, congestion and oedema of the submucosa and

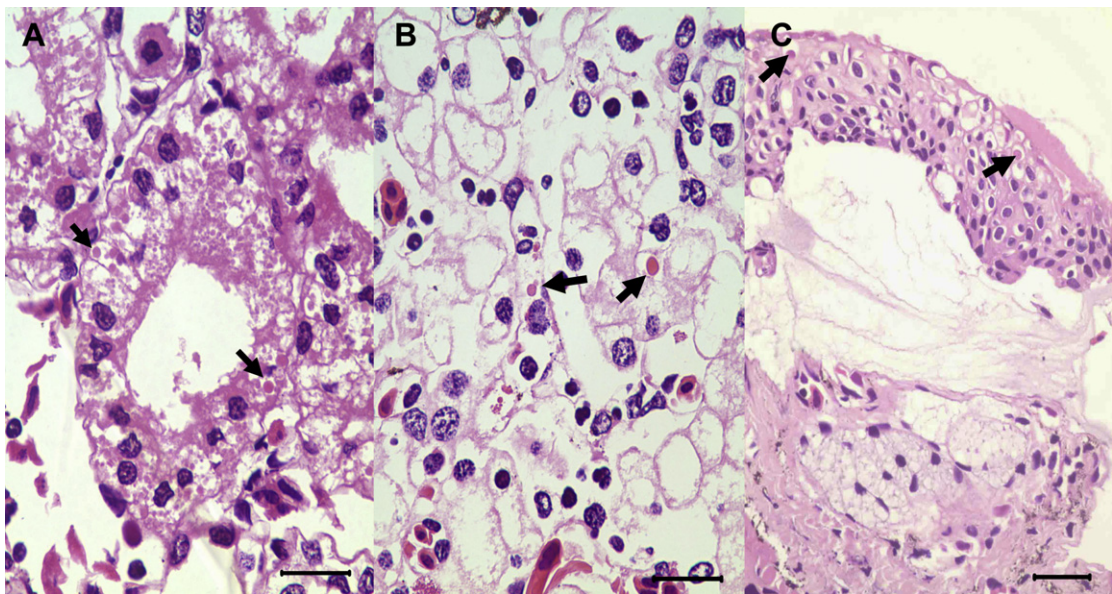


Fig. 2. Microscopical lesions in an infected Chinese giant salamander. (A) Intracytoplasmic inclusions (arrows) and necrosis of renal tubular epithelial cells. HE. Bar, 40 μm . (B) Intracytoplasmic inclusions (arrows) and vacuolar degeneration of hepatocytes. HE. Bar, 40 μm . (C) Intracytoplasmic inclusions (arrows) and oedema of epidermal cells of the skin. HE. Bar, 60 μm .

lamina propria, and ulceration were observed in the gastrointestinal tract. Ulceration was occasionally associated with haemorrhage into the gut lumen. Viral inclusions were occasionally seen in epithelial cells of the gastrointestinal tract. These severe lesions were responsible for the vomiting and bloody diarrhoea reported clinically in some animals. Skin lesions included intracellular and intercellular oedema of the stratum spinosum, which was frequently associated with areas of ballooning degeneration and necrosis. Cytoplasmic inclusions were noted in epidermal cells (Fig. 2C). Microscopical lesions in the skin correlated with the pale foci seen at necropsy examination. In some cases these lesions progressed to foci of erosion and ulceration. Diffuse acute necrosis of the spleen, with deposition of fibrin and obliteration of the normal splenic architecture, was observed.

The kidneys, livers and spleens from five diseased Chinese giant salamanders were selected for electron microscopical examination. Intracellular icosahedral 130–150 nm diameter iridovirus-like particles (Fig. 3) were found in 2/5, 4/5 and 5/5 spleens, livers and kidneys, respectively. The viruses were observed in various forms of assembly, including complete capsids (containing electron-dense forms), incomplete capsids and capsids associated with electron-dense material. The viruses were often found adjacent to swollen mitochondria and dilated rough endoplasmic reticulum (RER).

Bacteriological Examination

The bacteria *Aeromonas hydrophila*, *Aeromonas veronii*, *Citrobacter freundii*, *Acinetobacter* spp., *Acinetobacter*

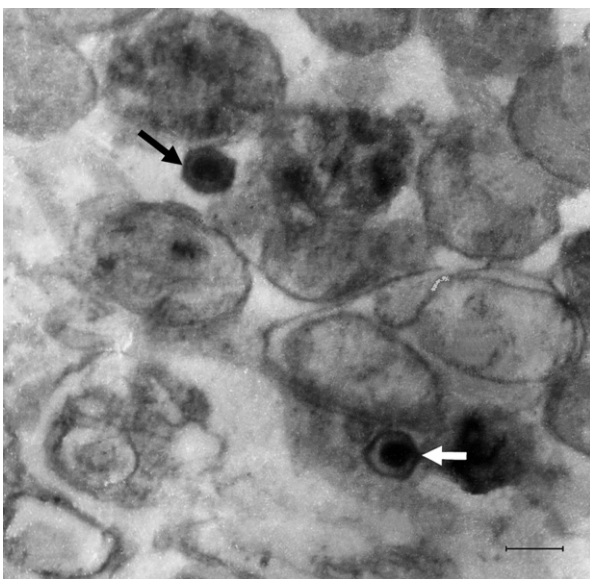


Fig. 3. Electron micrograph of the icosahedral iridovirus-like particles (arrow) noted in the hepatocytes of a Chinese giant salamander. Bar, 240 nm.

baumannii, *Acinetobacter lwoffii*, *Plesiomonas shigelloides* and *Enterobacter coli* were isolated from the lung, liver, kidney, spleen and skin lesions of some (but not all) diseased Chinese giant salamanders (Table 1). Some of the diseased Chinese giant salamanders were infected with one or more of these bacteria.

PCR for Ranavirus in Tissues

Liver and kidney tissues collected from six diseased Chinese giant salamanders were PCR positive for ranavirus. The 500 bp fragment of the ranavirus MCP gene in each test sample was amplified and then two of these fragments were selected randomly for direct sequencing. A GenBank BLAST search on the sequence revealed 95–98% identities to ranaviruses from amphibian: ATV (AY548301, EU512397, EU360297; 95%), FV3 (DQ897669, GQ144407; 96% and AY548484, FJ459783; 97%), *Rana esculenta* virus (FJ358611, FJ515796; 98%), common midwife toad ranavirus (FM213466; 98%) and *Rana catesbeiana* virus (FJ207464; 97% and AB474588; 98%).

Virus Isolation and PCR Detection of Ranavirus

EPC cells were inoculated with filtered tissue homogenates from four diseased Chinese giant salamanders. Cytopathic effect (CPE) was evident after incubation

Table 1
Bacteria isolated from affected Chinese giant salamanders at necropsy examination

Sample number	Development stage	Bacteria
1	Larva	<i>Aeromonas veronii</i> , <i>Acinetobacter baumannii</i>
2	Larva	None
3	Larva	<i>Aeromonas hydrophila</i> , <i>Citrobacter freundii</i>
4	Larva	None
5	Juvenile	<i>Aeromonas veronii</i> , <i>Acinetobacter</i> spp.
6	Juvenile	<i>Aeromonas hydrophila</i> , <i>Enterobacter coli</i>
7	Juvenile	<i>Enterobacter coli</i> , <i>Aeromonas hydrophila</i> , <i>Acinetobacter lwoffii</i>
8	Juvenile	<i>Plesiomonas shigelloides</i> , <i>Acinetobacter lwoffii</i> , <i>Enterobacter coli</i>
9	Juvenile	None
10	Adult	<i>Plesiomonas shigelloides</i> , <i>Citrobacter freundii</i>
11	Adult	<i>Aeromonas veronii</i> , <i>Acinetobacter</i> spp.
12	Adult	<i>Citrobacter freundii</i> , <i>Aeromonas hydrophila</i> , <i>Plesiomonas shigelloides</i>

for 5 days at 20°C. To verify that CGSV was a ranavirus, DNA was extracted from cultured EPC cells exhibiting CPE and then PCR-amplified using primers specific for highly conserved regions within the MCP gene of FV3 and other iridoviruses (Mao *et al.*, 1997). A 500 bp DNA fragment was amplified and sequenced. Sequence analysis revealed that the partial MCP gene obtained from CGSV was consistent with that from the tissues of the diseased Chinese giant salamanders.

Experimental Challenge

To confirm the pathogenicity, EPC-grown CGSV was used to infect five Chinese giant salamanders by IP inoculation. The infected salamanders died within 6–8 days. The clinical signs and post-mortem lesions in infected animals were similar to those described above. The CGSV was reisolated from all of the dead animals and was identified by PCR. These observations indicate that the CGSV is the aetiological agent of the disease.

Discussion

Based on a combination of clinical signs, characteristic microscopical lesions, transmission electron microscopical observations, virus isolation, molecular investigations and experimental challenge (Bollinger *et al.*, 1999; Balseiro *et al.*, 2009; Gray *et al.*, 2009; Miller *et al.*, 2009), we conclude that a ranavirus infection caused the disease outbreak in the farmed Chinese giant salamanders of this report. As far as we know, this is the first documented case of significant morbidity and mortality associated with a ranavirus in Chinese giant salamanders. Earlier reports of disease in Chinese giant salamanders do not mention virus examination. Wu *et al.* (2007) and Meng *et al.* (2009) described unusual deaths of Chinese giant salamanders in Guizhou Province and Zhejiang Province. The affected animals had red and swollen areas of erosion and ulceration on the head and limbs, and internal examination revealed diffuse haemorrhage in the kidney, liver, spleen and gastrointestinal tract. The aetiological agents of these outbreaks were identified as *Edwardsiella tarda* and *A. hydrophila*, respectively. However, virus testing was not attempted, so it is not known if an underlying ranavirus infection was present. In the present study, *A. hydrophila* and other bacteria were isolated from the organs of the diseased Chinese giant salamanders. However, these bacteria did not appear to be related to the gross and microscopical changes noted in the diseased salamanders, thus these organisms were likely incidental or secondary to the ranavirus infection (Cunningham *et al.*, 1996; Miller *et al.*, 2008).

The gross and microscopical effects of ranavirus infection of Chinese giant salamanders described in this paper were consistent with those reported in other salamanders (Bollinger *et al.*, 1999; Docherty *et al.*, 2003) and tadpoles (Gray *et al.*, 2007; Miller *et al.*, 2009). Severe lesions were observed in the skin, liver, kidney, gastrointestinal tract and lymphoid system. Although non-specific histological changes (i.e. minimal to mild lymphocytolysis, lymphoid depletion and mild vacuolation of hepatocytes and the renal tubular epithelium) were found in affected Chinese giant salamanders, extensive organ necrosis was observed in both larvae and adults, with the liver, spleen, kidney, heart and intestines being most affected. The lesions, including the presence of cytoplasmic inclusions in hepatocytes, epithelial cells and cardiac muscle fibres, were consistent with a lethal, sudden-onset viraemia with viral inclusions in almost all organs (Docherty *et al.*, 2003).

Mass mortality of amphibians due to ranavirus infection has been reported in the Americas, Europe and Asia (Cunningham *et al.*, 1996; Ariel *et al.*, 2009; Gray *et al.*, 2009; Une *et al.*, 2009b). Muths *et al.* (2006) reported that 43% of the reported amphibian mortality events in the USA from 2000 to 2005 were due to ranaviruses. Similarly, Green *et al.* (2002) reported that 57% of the mortality events investigated by the US Geological Survey National Wildlife Health Center from 1996 to 2001 were wholly or partially caused by ranaviruses. These data suggest that ranaviruses are widespread pathogens that are frequently associated with deaths of wild and captive amphibian populations. Ranaviruses are known to infect amphibians, reptiles and osteichthyan (bony) fish (Williams *et al.*, 2005a). Currently, six species of Ranavirus are recognized, three of which infect amphibians: FV3, *Bohle iridovirus* (BIV) and *Ambystoma tigrinum* virus (ATV) (Chinchar *et al.*, 2005). Majji *et al.* (2006) suggested the existence of a fourth possible species that infects amphibians (*Rana catesbeiana* virus Z, RCV-Z), based on restriction fragment length polymorphism profiles. Although electron microscopy and sequence analysis based on a 500 bp region of the MCP were performed in this study, the results are not definitive evidence that the virus from Chinese giant salamanders is a particular ranavirus species. Further study, including molecular characterization, defining the host range and protein profiles of the ranavirus infecting Chinese giant salamanders should be performed in order to determine whether it is a novel strain or species of the genus Ranavirus.

Ranavirus types are known to infect multiple hosts, but susceptibility varies among amphibian species (Schock *et al.*, 2008; Gray *et al.*, 2009). Schock *et al.*

(2008) reported that ATV was more pathogenic to salamanders than to anurans, and FV3 was more pathogenic to anurans than to salamanders. In this case, we found that the larvae of frogs (*Rana nigromaculata* and *Rana limnocharis*) and toads (*Bufo gargarizans*) from the same site were unaffected, and no morbidity was detected. This information suggests that the Ranavirus type that infected the Chinese giant salamanders may be species specific. Although iridovirus infections have been reported in amphibians (pig frog, *Rana grylio* and tiger frog, *Rana tigrina*) in China (Zhang *et al.*, 2001; Miao *et al.*, 2003), the source of infection in the present study could not be identified. However, this virus may be endemic to China and an epidemiological survey will be necessary to determine the source of the ranavirus that infected the Chinese giant salamander population of Hanzhong County. Further studies to develop rapid diagnostic methods and vaccines against the disease are required to better control ranavirus infection in Chinese giant salamanders.

Acknowledgments

This work was supported by the Program for Changjiang Scholars and Innovative Research Teams in the University (No. IRT0848), and the Science and Technology project of Sichuan Province (No. 08ZA082).

References

- Ariel E, Kielgast J, Svart HE, Larsen K, Tapiovaara H *et al.* (2009) Ranavirus in wild edible frogs *Pelophylax kl. esculentus* in Denmark. *Diseases of Aquatic Organisms*, **85**, 7–14.
- Balseiro A, Dalton KP, Cerro AD, Marquez I, Cunningham AA *et al.* (2009) Pathology, isolation and molecular characterisation of a ranavirus from the common midwife toad *Alytes obstetricans* on the Iberian Peninsula. *Diseases of Aquatic Organisms*, **84**, 95–104.
- Bigarré L, Cabon J, Baud M, Pozet F, Castric J (2008) Ranaviruses associated with high mortalities in catfish in France. *European Association of Fish Pathologists Bulletin*, **28**, 163–168.
- Bollinger TK, Mao J, Schock D, Brigham RM, Chinchar VG (1999) Pathology, isolation, and preliminary molecular characterization of a novel iridovirus from tiger salamanders in Saskatchewan. *Journal of Wildlife Diseases*, **35**, 413–429.
- Chinchar VG, Essbauer S, He JG, Hyatt A, Miyazaki T *et al.* (2005) *Virus Taxonomy: 8th Report of the International Committee on the Taxonomy of Viruses*. Elsevier, London, pp. 163–175.
- Collins JP, Storfer A (2003) Global amphibian declines: sorting the hypotheses. *Diversity and Distributions*, **9**, 89–98.
- Cullen BR, Owens L (2002) Experimental challenge and clinical cases of Bohle iridovirus (BIV) in native Australian anurans. *Diseases of Aquatic Organisms*, **49**, 83–92.
- Cunningham AA, Langton TES, Bennett PM, Lewin JF, Drury SEN *et al.* (1996) Pathological and microbiological findings from incidents of unusual mortality of the common frog (*Rana temporaria*). *Philosophical Transactions of the Royal Society of London Series B: Biological Sciences*, **351**, 1539–1557.
- Daszak P, Cunningham AA, Hyatt AD (2003) Infectious disease and amphibian population declines. *Diversity and Distributions*, **9**, 141–150.
- Docherty DE, Meteyer CU, Wang J, Mao J, Case S *et al.* (2003) Diagnostic and molecular evaluation of three iridovirus-associated salamander mortality events. *Journal of Wildlife Diseases*, **39**, 556–566.
- Douglas ED, Carol UM, Jun W, Mao JH, Steven TC *et al.* (2003) Diagnostic and molecular evaluation of three iridovirus-associated salamander mortality events. *Journal of Wildlife Diseases*, **39**, 556–566.
- Forson DD, Storfer A (2006) Atrazine increases ranavirus susceptibility in the tiger salamander, *Ambystoma tigrinum*. *Ecological Applications*, **16**, 2325–2332.
- Gray MJ, Miller DL, Hoverman JT (2009) Ecology and pathology of amphibian ranaviruses. *Diseases of Aquatic Organisms*, **87**, 243–266.
- Gray MJ, Miller DL, Schmutzer AC, Baldwin CA (2007) Frog virus 3 prevalence in tadpole populations inhabiting cattle-access and non-access wetlands in Tennessee, USA. *Diseases of Aquatic Organisms*, **77**, 97–103.
- Green DE, Converse KA, Schrader AK (2002) Epizootiology of sixty-four amphibian morbidity and mortality events in the USA, 1996–2001. *Annals of the New York Academy of Science*, **969**, 323–339.
- Jancovich JK, Davidson EW, Morado JF, Jacobs BL, Collins JP (1997) Isolation of a lethal virus from the endangered tiger salamander *Ambystoma tigrinum stebbinsi*. *Diseases of Aquatic Organisms*, **31**, 161–167.
- Majji S, LaPatra S, Long SM, Sample R, Bryan L *et al.* (2006) Rana catesbeiana virus Z (RCV-Z): a novel pathogenic ranavirus. *Diseases of Aquatic Organisms*, **73**, 1–11.
- Mao J, Hedrick RP, Chinchar VG (1997) Molecular characterization, sequence analysis, and taxonomic position of newly isolated fish iridoviruses. *Virology*, **229**, 212–220.
- Matthew JG, Debra LM (2009) First report of ranavirus infecting lungless salamanders. *Herpetological Review*, **40**, 316–319.
- Meng Y, Zeng LB, Yang YQ, Xiao HB (2009) Isolation and identification of the ascite sosis disease pathogen of giant salamander, *Andrias davidianus*. *Journal of the Northwest Agricultural and Forestry University*, **37**, 77–81.
- Miao SY, Wang XH, Ye QZ (2003) Study on the morphology and pathogenicity of the virus isolated from tiger frog, *Rana tigrina*. *Acta Scientiarum Naturalium Universitatis Sunyatseni*, **42**, 69–73.
- Miller DL, Gray MJ, Rajeev S, Schmutzer AC, Burton EC *et al.* (2009) Pathological findings in larval and juvenile anurans inhabiting farm ponds in Tennessee, USA. *Journal of Wildlife Diseases*, **45**, 314–324.

- Miller DL, Rajeev S, Brookins M, Cook J, Whittington L *et al.* (2008) Concurrent infection with *Ranavirus*, *Batrachochytrium dendrobatidis*, and *Aeromonas* in a captive anuran colony. *Journal of Zoo and Wildlife Medicine*, **39**, 445–449.
- Muths E, Gallant AL, Campbell EHC, Battaglin WA (2006) *The Amphibian Research and Monitoring Initiative (ARMI): 5-year report*. US Geological Survey scientific investigations report 2006–5224.
- Picco AM, Collins JP (2008) Amphibian commerce as a likely source of pathogen pollution. *Conservation Biology*, **22**, 1582–1589.
- Pozet F, Morand M, Moussa A, Torhy C, de Kinkelin P (1992) Isolation and preliminary characterisation of a pathogenic icosahedral deoxyribovirus from the catfish *Ictalurus melas*. *Diseases of Aquatic Organisms*, **14**, 35–42.
- Regal PJ (1966) Feeding specializations and the classification of terrestrial salamanders. *Evolution*, **20**, 392–407.
- Schock DM, Bollinger TK, Chinchar VG, Jancovich JK, Collins JP (2008) Experimental evidence that amphibian ranaviruses are multi-host pathogens. *Copeia*, **1**, 133–143.
- Storfer A, Alfaro ME, Ridenhour BJ, Jancovich JK, Mech SG *et al.* (2007) Phylogenetic concordance analysis shows an emerging pathogen is novel and endemic. *Ecology Letters*, **10**, 1075–1083.
- Une Y, Nakajinma K, Taharaguchi S, Ogihara K, Murakami M (2009a) Ranavirus infection outbreak in the salamander (*Hynobius nebulosus*) in Japan. *Journal of Comparative Pathology*, **141**, 310.
- Une Y, Sakuma A, Matsueda H, Nakai K, Murakami M (2009b) Ranavirus outbreak in North American bullfrogs (*Rana catesbeiana*), Japan. *Emerging Infectious Diseases*, **15**, 1146–1147.
- Wang XM, Zhang KJ, Wang ZH, Ding YZ, Wu W *et al.* (2004) The decline of the Chinese giant salamander *Andrias davidianus* and implications for its conservation. *Oryx*, **38**, 197–202.
- Williams T, Barbosa-Solomieu V, Chinchar GD (2005a) A decade of advances in iridovirus research. In: *Advances in Virus Research*, K Maramorosch, A Shatkin, Eds., Academic Press, New York, pp. 173–248.
- Williams T, Barbosa-Solomieu V, Chinchar VG (2005b) A decade of advances in iridovirus research. *Advances in Virus Research*, **65**, 173–248.
- Wu ZM, Wang H, Ao DS, Wang Y, Wang ML (2007) Infection of *Andrias davidianus* with *Edwardsiella tarda*. *Acta Academiae Medicinae Zunyi*, **30**, 464–466.
- Zhang QY, Xiao F, Gui JF, Mao J, Chinchar VG (2001) Characterization of an iridovirus from the cultured pig frog, *Rana grylio*, with a lethal syndrome. *Diseases of Aquatic Organisms*, **48**, 27–36.

[Received, August 3rd, 2010
Accepted, November 23rd, 2010]